



MAX - IMPACT

The Official Newsletter of
AOMSI Delhi- NCR State Chapter

Issue 4, February 2025

AOMSI Head Office Bearers

President	: Dr. Manikandhan
Hon. Gen. Secretary	: Dr. S Girish Rao
President Elect	: Dr. Ashish Gupta
Hon. Treasurer	: Dr. Rajasekhar Gaddipati
Hon. Editor	: Dr. Amit Dhawan

OFFICE BEARERS OF AOMSI DELHI NCR STATE CHAPTER

President	: Dr. Gagan Khare
Hon. Secretary	: Dr. Imran Khan
President Elect	: Dr. Apoorva Mowar
Immediate Past President	: Dr. Rohit Chandra
Vice President	: Dr. Puneet Kalra
Treasurer	: Dr. Vidhi C Rathi
Secretary Elect	: Dr. Zainab Chaudhary
Treasurer Elect	: Dr. Lokesh Chandra
Joint Secretary	: Dr. Mukesh Soni
Representative to the National Body	: Dr. Nitin Bhagat
Editor	: Dr. Deborah Sybil

EXECUTIVE COMMITTEE MEMBERS

Dr. Ashish Sharma
Dr. Anshul Jain
Dr. Shabbu Garg
Dr. Gourav Popli
Dr. Bhavya Mishra
Dr. Arun Mishra
Dr. Shreya Krishna
Dr. Harsh Deep Singh
Dr. Karan Sublok
Dr. Siddharth Rawat





Message From the PRESIDENT AOMSI Delhi NCR State Chapter

"Success is best when it's shared." Howard Schultz

Dear Members,

It is with great pride that I share the 4th edition of Max Impact, the newsletter of AOMSI-Delhi NCR State Chapter. This milestone reflects the dedication and collaboration spirit of our community, united in its commitment to excellence.

I extend heartfelt gratitude to the editorial team for their tireless efforts in curating this edition and to our members for their valuable contributions. Your active participation underscores the strength of our shared mission to advance speciality of oral and maxillofacial surgery,

Our state chapter plays a pivotal role in establishing the identity of oral and maxillofacial surgeons among the general population and other medical specialties. As Albert Schweitzer said, "Wherever you turn, you can find someone who needs you." Let us use our skills and expertise to serve, educate, and create awareness about the vital contributions of our specialty to healthcare.

I urge call members to explore the unexplored avenues of our specialty, embracing innovation and pushing the boundaries of what we can achieve. Whether through advanced research, novel surgical techniques, or interdisciplinary collaborations, there are limitless opportunities to elevate our practice and make a lasting impact.

Through public awareness campaigns, community outreach, and educational programs, we can highlight our role in addressing facial trauma, oral cancer, craniofacial deformities, and dental implantology. Collaborating with other medical specialties through interdisciplinary initiatives will further reinforce our importance in holistic patient care.

To our young surgeons, remember the words of Eleanor Roosevelt: "The future belongs to those who believe in the beauty of their dreams." Your passion and innovation are the driving forces behind the future of our specialty.

As John C. Maxwell wisely said, "Teamwork makes the dream work." Let us extend our collaboration among all members, sharing ideas and resources to propel our state chapter to new heights. Together, we can create a robust and unified community dedicated to excellence in speciality of oral and maxillofacial surgery.

Thank you for being an integral part of this journey. Let us celebrate this edition of Max Impact as a testament to what we can accomplish together.

Warm regards,

Dr. Gagan Khare

President

AOMSI Delhi NCR State Chapter



Message

From the HON. SECRETARY AOMSI Delhi NCR State Chapter

"Alone we can do little; together we can do so much." - Helen Keller

Dear Members,

It gives me great pleasure to present the 4th edition of Max Impact, the newsletter of AOMSI-Delhi NCR State Chapter.

This edition is a testament to the hard work of our editorial team and the invaluable contributions of our members. It serves as a dynamic platform for sharing knowledge and experiences in oral and maxillofacial surgery, reflecting the strength and commitment of our community.

Aligned with the National AOMSI theme for this year celebrating **International Oral and Maxillofacial Surgery Day** on 13th February 2025, **"Early Detection and Prevention of Oral Cancer,"** our chapter will organize meaningful events to mark this important day. These programs aim to promote awareness about the importance of early detection by engaging schools, community groups, and social organizations. I encourage all members to actively organize and participate in these events under the aegis of the AOMSI-Delhi NCR State Chapter.

Looking ahead, I urge you to represent our chapter on both national and international platforms. Key events include the **ICOMS in Singapore (22-25 May 2025)**, **27th MIDCOMS in Agra (10-12 July 2025)**, and the **49th National AOMSI Conference in Vizag (11-13 December 2025)**. Participation in these prestigious gathering will not only enhance your knowledge and foster collaboration but also elevate the presence of our chapter on a larger stage.

By working together with unity, fostering mentorship, and striving for excellence, we can ensure that the Delhi NCR State Chapter remains a driving force in advancing oral and maxillofacial surgery and bringing laurels to our community.

With warm regards,

Dr. Imran Khan

Hon. Secretary

AOMSI-Delhi NCR State Chapter



Message From the EDITORIAL TEAM

"Coming together is a beginning, staying together is progress, and working together is success." Henry Ford

Greetings from the editorial team of Max Impact!

We are delighted to present the 4th edition of the newsletter of the Delhi NCR State Chapter of the Association of Oral and Maxillofacial Surgeons of India (AOMSI). This edition reflects the collective efforts and unwavering support of our esteemed office bearers and chapter members.

As Albert Schweitzer said, "The purpose of human life is to serve, and to show compassion and the will to help others." We extend heartfelt gratitude to the office bearers of the AOMSI Delhi NCR Chapter for their guidance and encouragement. Their vision and commitment to advancing our specialty have been instrumental in shaping this publication.

A special thanks to the contributors who enriched this edition with their insights, research, and updates. As Margaret Fuller once said, "If you have knowledge, let others light their candles in it." Your efforts ensure this newsletter remains a valuable platform for sharing ideas, experiences, and advancements in oral and maxillofacial surgery.

To our young maxillofacial surgeons, remember Theodore Roosevelt's words: "Believe you can, and you're halfway there." Your enthusiasm and dedication inspire us all. Embrace challenges as opportunities for growth and innovation, as your efforts will shape the future of our field.

We look forward to your continued support and contributions to Max Impact. Together, let us strengthen our shared mission of professional excellence and camaraderie. As Helen Keller wisely said, "Alone we can do so little; together we can do so much."

Warm regards,

Editorial Team

Max Impact

AOMSI Delhi NCR State Chapter



Dr. Deborah Sybil



Dr. Karan Sublok



Dr. Harsh Deep Singh



Newly elected “President-elect”

We are honored to present this conversation with **Dr. Ashish Gupta**, the Newly elected “President-elect” of AOMSI, marking a historic milestone for the Delhi NCR State Chapter after 21 years. Driven by unwavering commitment, he envisions transforming oral and maxillofacial surgery into a household name, promoting collaborative expertise and cutting-edge innovations. Join us as he shares his journey, plans for nationwide awareness, and strategies to shape the future of OMFS in India.

Q.1. Many congratulations on your election as President AOMSI. How significant is this victory for you, Sir?

Ans. This victory holds immense significance for me, as it marks the election of a President from the AOMSI Delhi NCR State Chapter after a long gap of 21 years. It is not just a personal achievement, but a testament to the collective hard work, dedication, and perseverance of all our chapter members over these years. Their unwavering commitment and efforts have played a pivotal role in making this milestone possible, and I am truly honored to represent our chapter at this esteemed position.

Q.2. What is your vision for AOMSI?

Ans. AOMSI is already a robust and dynamic organization with over 10,000 dedicated members, and it continues to grow stronger every day. My vision for AOMSI is to elevate its presence and recognition to a level where it becomes a household name - a trusted entity that the general public can easily associate with oral and maxillofacial surgery. I aim to bridge the gap between our specialty and the community by enhancing awareness, accessibility, and understanding of the vital role our profession plays in healthcare. Through strategic outreach, education, and collaboration, I envision AOMSI becoming the go-to authority for oral and maxillofacial care in India and beyond.

Q.3. The head and neck region is a shared workspace for many surgeons - ENT, plastics, ophthalmologists, neurosurgeons, oncologists and others. What steps would you want to take as President, AOMSI to foster harmonious collaboration between specialities?

Ans. Collaboration with specialists like ENT surgeons, plastic surgeons, ophthalmologists, neurosurgeons, and oncologists is essential for better patient care and professional growth. As President of AOMSI, my goal is to build **better relationships and teamwork** with these specialties through open communication and shared learning.

One way to achieve this is by **inviting experts from other fields to teach our members** and, in return, our specialists can contribute to their programs. This exchange of knowledge will help us understand each other's strengths and create mutual respect.

Instead of blaming or competing, we need to **focus on working together** and finding solutions to challenges through regular discussions. I will work towards strengthening our connections with other specialties at both national and association levels to remove barriers and create a friendly working environment.

In the end, there is enough work for everyone, and by collaborating, we can provide the best possible care for our patients.

Q.4. In your opinion, what is the next big thing in the field of maxillofacial surgery?

Ans. Maxillofacial surgery is evolving rapidly, with significant advancements shaping the future of the field. In my opinion, the **next big breakthrough will be the integration of Artificial Intelligence (AI) and Robotics**, similar to what we are witnessing in other medical specialties. These technologies have the potential to revolutionize diagnosis, treatment planning, and surgical precision, ultimately leading to better patient outcomes.

Additionally, **research and innovation** will play a crucial role in the future of maxillofacial surgery. Continuous advancements in areas such as regenerative medicine, 3D printing, and minimally invasive techniques will open new possibilities for patient care. Embracing these cutting-edge technologies and fostering a culture of research will ensure that our specialty remains at the forefront of modern healthcare.



Q.5: What measures would you like to implement at a national level to improve awareness of our field among the masses?

Ans: To increase awareness of Oral and Maxillofacial Surgery (OMFS) nationwide, we need a clear and consistent strategy using various media and outreach efforts.

Firstly, **continuous awareness programs** in schools, workplaces, and public spaces will help educate people about the role and importance of OMFS in healthcare.

Secondly, **social media and influencers** can play a key role in spreading awareness. Engaging content such as podcasts, videos, and live sessions on platforms like YouTube, Instagram, and Facebook can reach a wider audience effectively.

Traditional media, including **newspapers, magazines, radio, and TV**, should also be used to reach those who may not be active online. Expert interviews and feature articles can help inform the public about our specialty.

Finally, working with **health organizations, government agencies, and NGOs** will help integrate OMFS into public health initiatives, ensuring wider reach and impact.

By combining digital, print, and community outreach efforts, we can make OMFS a well-known and trusted specialty across the country.

Q.6.: What do you think is the role of state chapters of AOMSI, especially the Delhi-NCR state chapter? Where do you see it in the next five years?

Ans: The state chapters of AOMSI, especially the Delhi-NCR chapter, play a crucial role in **promoting oral and maxillofacial surgery at the regional level** and ensuring greater public awareness about our specialty. Our chapter is already performing exceptionally well, and we are committed to continuing this momentum with focused efforts.

With the dedicated leadership and positions we hold within the association, we have a great opportunity to **enhance our presence, engage more with the public, and create greater awareness** about the scope and importance of OMFS. Through consistent academic activities, awareness programs, and collaboration with healthcare institutions, we can strengthen our impact further.

In the next five years, I envision the Delhi-NCR chapter becoming **one of the most influential and recognized chapters** in the country. Our goal is to make OMFS a household name in the region, ensuring that both the public and healthcare community recognize our expertise and contributions. With continued dedication, teamwork, and strategic initiatives, our chapter will set an example for others and achieve new heights of success.

Q.7: What is your message to young budding maxillofacial surgeons?

Ans: My message to young maxillofacial surgeons is to **focus on continuous learning and skill enhancement** to excel in this dynamic field. They should actively seek opportunities to learn, practice, and refine their skills, always striving to take their expertise to the next level.

I strongly encourage them to **work closely with senior professionals**, observe, and absorb their knowledge and experience. Mentorship is invaluable in shaping a successful career, as it provides practical insights that cannot be learned from textbooks alone.

Most importantly, they must understand that **there are no shortcuts to success**. In today's highly competitive healthcare landscape, challenges are everywhere, and true success comes from **dedication, perseverance, and a commitment to excellence**. Staying patient, resilient, and constantly evolving with new advancements will pave the way for a rewarding career in maxillofacial surgery.

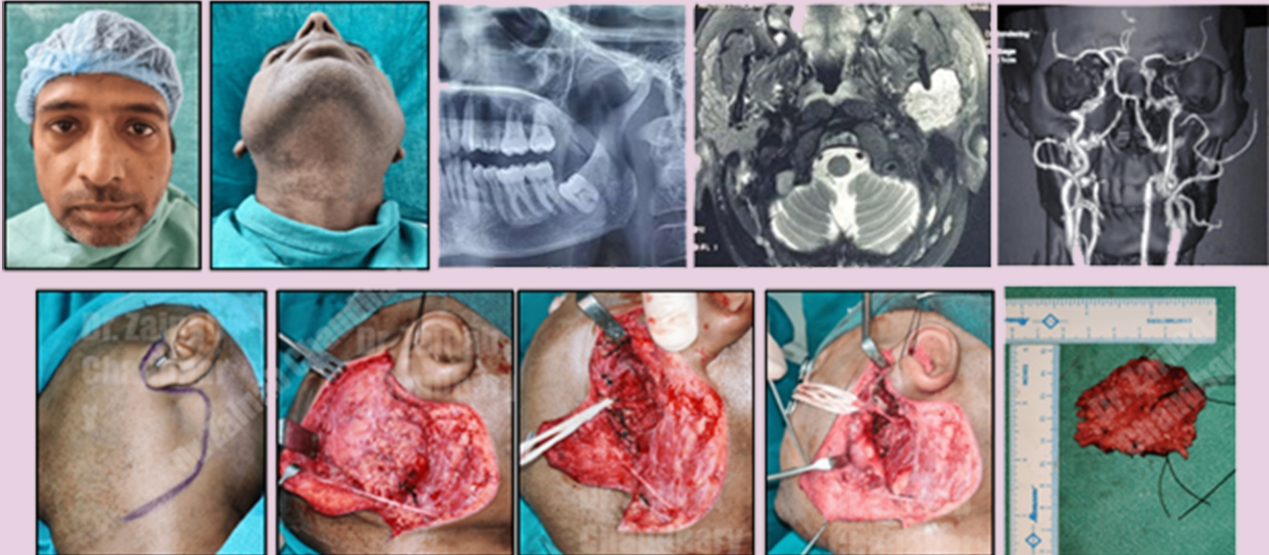


SURGICAL UPDATE

PAROTID LYMPHANGIOMA IN ADULT- A RARE CASE ENTITY

Contributed by : Dr. Zainab Chaudhary¹, Dr. Pankaj Sharma¹, Dr. Harshita Joshi²

¹ Professor, Dept of OMFS, MAIDS ² Post-Graduate, Dept of OMFS, MAIDS



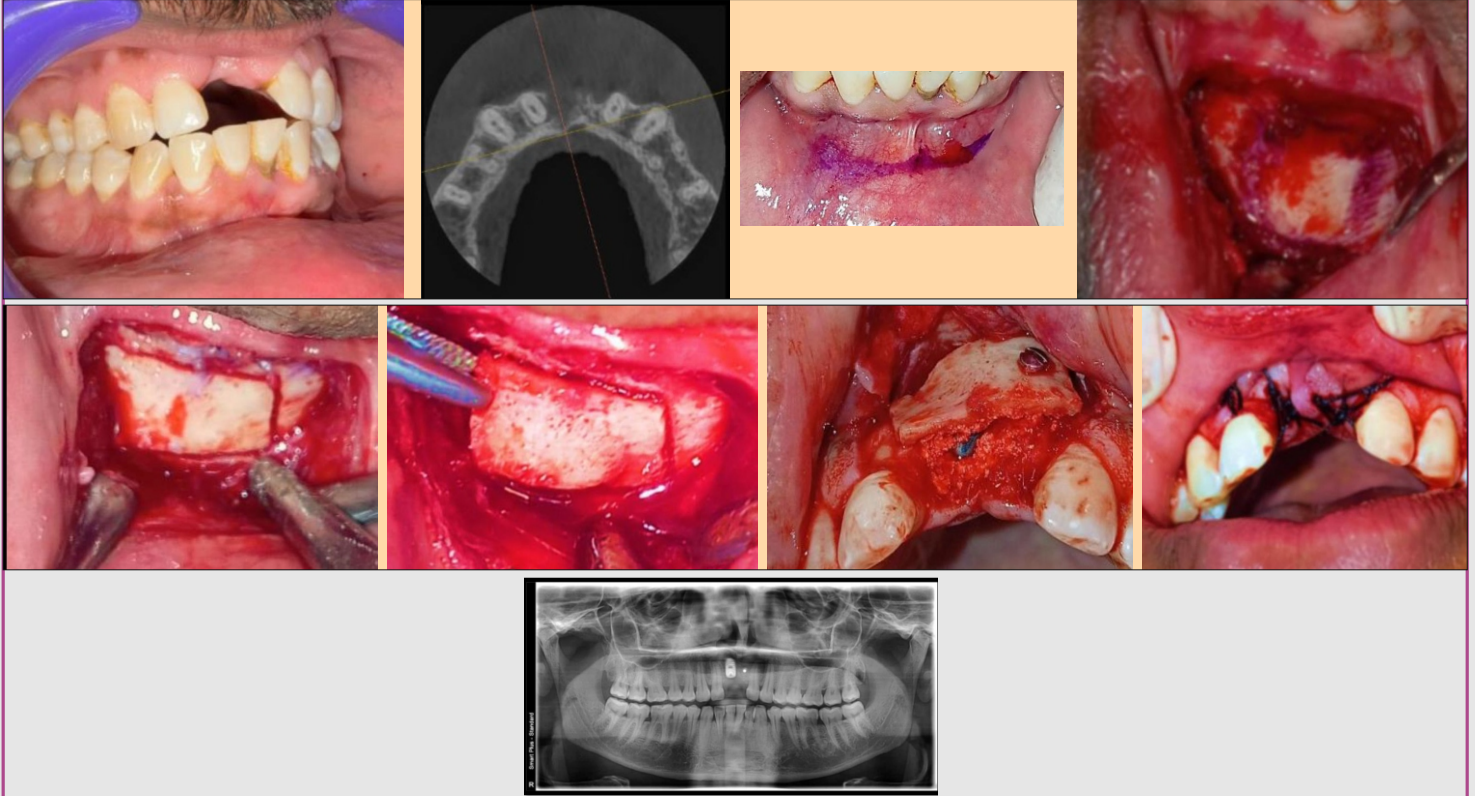
We present a case report of a 42-year-old male with a chief complaint of painful swelling in front of the left ear and gradual reduction in mouth opening since 5 years. Extraoral examination revealed diffuse, firm, tender, non-compressible swelling measuring approximately 3x2 cm in the left pre-auricular region. The maximal interincisal opening was 26 mm. No facial nerve weakness was apparent. FNAC of the pre-auricular swelling was performed, and it was suggestive of reactive lymphoid hyperplasia. Panoramic radiograph revealed depression in the posterior border of the left ramus suggesting resorptive change. Contrast enhanced MRI of the TMJ revealed well defined lobulated lesion, measuring approximately 33x32x35 mm appearing heterogeneously hyper intense on T2W/ STIR images and isointense on T1W. It was seen along the posterior aspect of the left mandibular condyle arising predominantly from the deep lobe of the parotid gland with superiorly extending up to the TMJ, posteriorly up to the pre-styloid region and medially abutting the lateral pterygoid muscle. CT angiography of the face and neck revealed terminal part of the left external carotid artery (ECA) entering into the lowermost margin of the tumour and then dividing into the terminal branches within the tumour as internal maxillary and superficial temporal artery. Total parotidectomy was scheduled under general anaesthesia. Modified Blair's incision was given, and the superficial cervicofacial flap was raised up to SMAS. Skeletonization of sternocleidomastoid, posterior belly of digastric, cartilage of external auditory canal up to the tragal pointer and mastoid tip was performed, which aided in the identification of location of the facial nerve. External jugular vein and External carotid artery was identified and ligated. Using blunt dissection, superficial lobe of the parotid gland was dissected from the branches of the facial nerve. Deep lobe of the parotid along with the tumour was separated from the condyle and lateral pterygoid muscle and it was delivered between the splayed branches of the facial nerve. Layer-wise primary closure was achieved and suction drain was placed. Both superficial and deep lobes of the parotid were sent for histopathological examination which revealed normal salivary gland architecture of superficial lobe and cavernous lymphangioma of deep lobe of parotid. The post-operative course remained uneventful except for facial nerve weakness with House-Brackmann score 3 in the immediate post-operative period. The patient was kept on a tapering course of injectable steroids followed by oral steroids for 20 days along with mecobalamin 1500 mcg once daily. His House-Brackmann score improved to 2 in the post-operative 6-month period. Mouth opening improved to 37 mm.



SURGICAL UPDATE

Merging Technology and Technique: Piezoelectric-Assisted Chin Grafting for Implant Site Optimization

Contributed by: *Dr Karan Sublok*
Reader, Shree Bankey Bihari Dental College, Ghaziabad



A 28 year old male presented to the Department of Oral and Maxillofacial Surgery with the chief complaint of missing maxillary anterior teeth. Clinical and radiographic evaluation, including cone-beam computed tomography (CBCT), revealed significant bone deficiency with the absence of the buccal cortical plate at the proposed implant site. To address the defect and facilitate implant placement, a treatment plan was advised for the placement of a conventional implant along with autogenous bone grafting harvested from the chin using piezoelectric surgery, as per the protocol described by Desai et al.

Under local anesthesia, a 1.5 cm autogenous bone graft was harvested from the symphysis region using a piezoelectric surgical unit to ensure precise and atraumatic removal. The harvested graft was contoured and secured at the recipient site using a 8 mm monocortical titanium screw to augment the deficient alveolar ridge with beta tricalcium phosphate of amount 60 mg. An implant was subsequently placed at the site with an insertion torque of 30 Ncm, ensuring primary stability. Primary closure was achieved using 3-0 silk sutures for both the donor site and the implant recipient site. Postoperative evaluation included an orthopantomogram (OPG), which confirmed appropriate graft placement and implant stability.

This case highlights the clinical utility of autogenous symphyseal graft harvested with piezoelectric unit in addressing challenging alveolar ridge deficiencies. The incorporation of precise surgical techniques and the achievement of optimal implant stability contributed to a predictable and successful outcome, demonstrating the effectiveness of this approach in complex oral rehabilitation cases.



8th Annual State Conference of AOMSI Delhi NCR State Chapter

The majestic ambiance of Hotel The Suryaa, New Friends Colony, served as the splendid backdrop for the 8th Annual State Conference of the Association of Oral and Maxillofacial Surgeons of India (AOMSI), Delhi NCR State Chapter on 22nd September, 2024. This illustrious gathering welcomed over 250 distinguished oral and maxillofacial surgeons, plastic surgeons, ENT specialists, and aspiring postgraduate students from across the vibrant landscape of Delhi NCR and beyond. Under the resplendent theme “Restoring Form, Function & Aesthetics,” the conference illuminated the latest advancements and best practices in the art and science of maxillofacial surgery, celebrating remarkable innovations in reconstructive techniques, pathology, and facial aesthetics.

The event was inaugurated by Prof. Mohammed Shakeel, officiating Vice Chancellor of Jamia Millia Islamia, who served as the Chief Guest. Adding to the grandeur, Dr. Bhagvandas Rai, President of AOMSI, graced the event as the Guest of Honour. With fervor, he emphasized the expanding and pivotal role of oral and maxillofacial surgeons in aesthetic procedures, encompassing hair transplants, Botox, fillers, and thread lifts, thus broadening the horizons of their practice.

Under the diligent leadership of a dedicated organizing committee including Dr. Rohit Chandra, Dr. Anurag Singh, Dr. Imran Khan, Dr. Ashish Gupta, Dr. Vidhi Rathi, Dr. Zainab Choudhary, and Dr. Deborah Sybil the conference unfolded with a rich tapestry of sessions led by eminent surgeons. Key presentations on infection, pathology, cancer, and reconstruction were delivered by distinguished speakers such as Dr. Akhilesh K Singh, Dr. Nitin Verma, Dr. Amit Dhawan, Dr. Senthil





Murugan, Dr. Nitin Bhola, and Lt. Col. Dr. Gopal Krishnan. These experts shared invaluable insights, addressing critical topics like antimicrobial resistance, the management of complex pathologies, and cutting-edge reconstructive techniques.

The sessions on implantology were particularly engaging, featuring Dr. Sankalp Mittal, Dr. Divye Malhotra, and Dr. Kiran K Boyina. Their expertise shed light on innovative approaches and the latest advancements in implant techniques, captivating the audience with their insights. Equally compelling were the discussions on facial aesthetics, led by luminaries such as Dr. Ajoy Roy Choudhary, Dr. Manu Prasad, Col. Dr. Vishal Gupta, and Dr. Mukul Padhaye. Their presentations explored the nuances of orthognathic surgery and the integration of medical micropigmentation, further broadening the scope of aesthetic procedures within maxillofacial practice.

With the presence of over 250 delegates, including enthusiastic postgraduate students and seasoned professionals from diverse medical disciplines, the conference emerged as a resounding success. It served as a vibrant reminder of the importance of continuous learning and collaboration in advancing the field of maxillofacial surgery in India. The conference also featured an impressive exhibition by leading medical market leaders, showcasing the latest innovations in maxillofacial surgical equipment and techniques. This remarkable gathering not only highlighted the strides made in the field but also reinforced a shared commitment to excellence, collaboration, and the relentless pursuit of knowledge in the ever-evolving landscape of oral and maxillofacial surgery.





Cadaveric Craniofacial Distraction hands-on Course

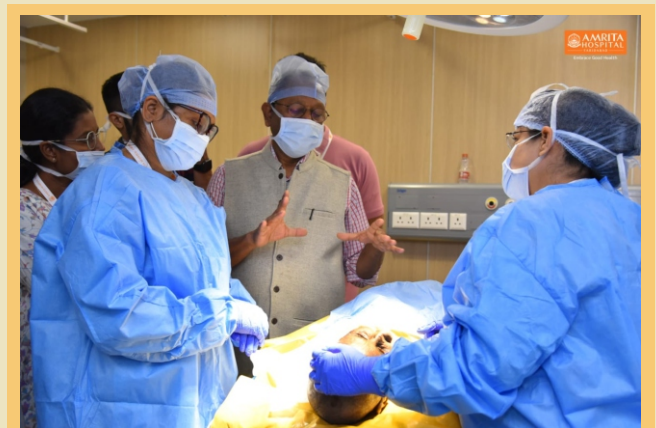

The Department of Plastic & Reconstructive Surgery at Amrita Hospital conducted its first “Cadaveric Craniofacial Distraction hands-on Course” on November 15 & 16, 2024. The course was led by the Craniofacial team at Amrita Hospital, Faridabad comprising of Dr Anil Murarka (Plastic Surgeon), Dr Arun Sharma (Oral & Maxillofacial Surgeon), Dr Sachin Gupta (Paediatric Neurosurgeon), and Dr Aditi Poddar Sharma (Orthodontist). It was conducted under the joint aegis of Association of Oral & Maxillofacial Surgeons of India - Delhi NCR State Chapter and Association of Plastic Surgery Delhi State Chapter. The course was well supported by KLS Martin, India. The invited faculty were - Dr Pramod Subash (Craniofacial unit head, Amrita Hospital, Kochi) and Dr Arjun Krishnadas (Consultant Craniofacial Surgeon, Amrita Hospital, Kochi).

The course saw active participation from 18 surgeons of both specialties - Plastic Surgery and Oral & Maxillofacial Surgery- travelling from all corners of the country and abroad. The first day involved CME-only wherein different distraction appliances were demonstrated and techniques were described through a combination of lectures and videos. The invited faculties and the hosts took turns to deliver lectures on different types of distraction techniques employed in the



craniomaxillofacial region. KLS Martin, India brought a vast range of distractors for exhibition and table discussion. The course faculty described each distractor, its components and applications in detail. There were additional lectures on anesthetic considerations and the role of Paediatric intensivist with the comprehensive management of craniofacial patients. The second day consisted of hands-on training on Synbone models and cadaver. Lefort III osteotomy and application of calvarial and mandibular distractor was performed by participants on either synbone model or cadaver. The course was well received by all participants.





AOMSI Delhi NCR cricket team wins Kolkata Tournament

AOMSI Delhi NCR cricket team travelled to Kolkata to participate in the Kolkata Conference Cricket tournament being held on 10th December at Cricket Maidans near Eden Garden Cricket Stadium.

It was a 6 team tournament with UP AOMSI, TN AOMSI, Kerala AOMSI, Andhra AOMSI and east-west zone AOMSI being the other teams participating.

In the road to the finals, Team AOMSI Delhi NCR defeated Team east-West Zone AOMSI & in the finals team AOMSI Delhi NCR defeated team Andhra AOMSI convincingly by 8 wickets.

AOMSI Delhi NCR team is the Cricket Tournament Champions at the 48th AOMSI Conference Kolkata, Team Played under the dynamic leadership of Dr Rohit Chandra.

In the final, team Andhra batted 1st and scored 127 runs in 15 overs.

Team AOMSI Delhi NCR chased the target in 13.3 overs.

Batting Stars of the Final were Dr Athreya Rajagopal and Dr Rohit Chandra who guided the team towards the winning total.

Dr Vikash Jha was awarded the Bowler of the Tournament trophy.

Dr Imran Khan was awarded the Fielder of the Tournament trophy.

This Victory is another feather in the Cap of the team.

The team now travels to Jabalpur in mid-February 2025 to compete in the AOMSI Cricket League.

Wishing our team the very best





AOMSI Badminton Tournament 2024

The AOMSI Badminton Tournament 2024 held in Kolkata on 11th December 2024 witnessed a spectacular showcase of talent, camaraderie, and sportsmanship at its finest. Enthusiastic participants from across the nation gathered in Kolkata to compete in both singles and doubles categories, making the event a grand success.

Highlights of the Tournament

Singles Winner:

Dr. Nitin Bhagat from Delhi emerged as the champion in the singles category. Demonstrating exceptional skill, determination, and endurance, Dr. Bhagat dominated the court, winning all 8 of his matches to secure the title. His performance captivated the audience and set a benchmark for excellence in the tournament.

Doubles Winner:

The doubles category was equally thrilling, with the dynamic duo of Dr. Nitin Bhagat and Dr. Uday clinching the title. The pair displayed impeccable coordination and strategy, winning all 4 of their matches and proving to be an unbeatable team.

Performance Overview

Dr. Nitin Bhagat's participation was the highlight of the tournament, as he played a total of 12 matches (8 singles and 4 doubles). His consistency, stamina, and versatility on the court were unmatched, making him a standout performer in both categories.

Conclusion

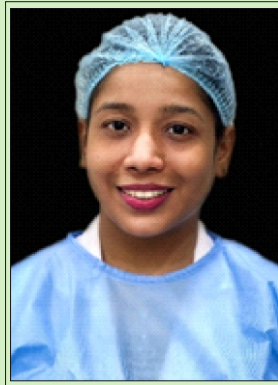The tournament successfully fostered a spirit of healthy competition and unity among the participants. The event concluded with a prize distribution ceremony, where Dr. Nitin Bhagat was honored for his exceptional achievements in both singles and doubles categories.

The AOMSI Badminton Tournament 2024 will undoubtedly be remembered for its thrilling matches, enthusiastic participation, and the remarkable performance of its winners.





Welcome Aboard: New Member Updates



Dr. Saloni Gupta

MDS OMFS, AOMSI fellow – Orthognathic Surgery 2022

Significance of AOMSI

AOMSI provides young maxillofacial surgeons with education, mentorship, and networking opportunities through workshops, seminars, and fellowships. It supports research, policy advocacy, and offers social security, while enabling international fellowship opportunities for professional growth and career advancement. For young oral and maxillofacial surgeons, being a member of a professional association is much more than a formal affiliation—it's a powerful tool for growth and success. It provides access to ongoing education, professional networking, advocacy, research, and leadership opportunities. Ultimately, this membership supports their journey toward becoming highly skilled, well-rounded, and respected practitioners in the field.



Prof. Dr. Sonia Chawla

NABH Assessor ,WCOI Diplomate

Editor- IDA East Delhi , Director – Chawla Dental and Implant Clinic, Delhi

OMFS contribution to society

Oral & Maxillofacial Surgeons play a vital role in enhancing society's oral health. They are key to tobacco awareness, educating people on its harmful effects while ensuring early detection of oral cancer through screenings and follow-ups, minimizing morbidity. Another critical contribution is preventing sports Injuries. By educating children, parents, and staff on the importance of protective sports gear, they help reduce trauma and safeguard young athletes. With their expertise, they don't just treat but empower society with knowledge, prevention, and care, shaping a healthier future.



Welcome Aboard: New Member Updates



Dr. Chayanika Sharma
O.M.F.S Consultant, South Delhi

Expectation from AOMSI

AOMSI has played a pivotal role in shaping our field, thanks to the remarkable contributions of our seniors. Moving forward, I hope to see more hands-on surgical workshops to further refine our skills. Additionally, I would appreciate structured guidance on post-PG career paths, including opportunities for academic affiliations, fellowships, and private practice. Expanding fellowship centers across India would make specialized training more accessible to all. Moreover, mentorship in setting up independent practices would be incredibly valuable for young surgeons like me. AOMSI has set a high standard, and I look forward to continuing to grow, create more opportunities, and strengthen our network of maxillofacial surgeons in India.



Dr. Gopal Jee
Creative Max Aesthetics, Dwarka

Significance of AOMSI

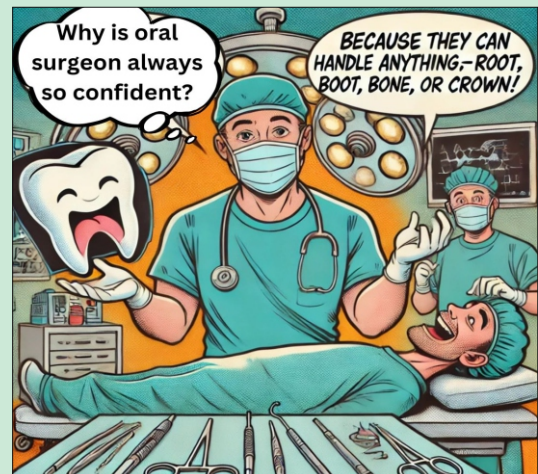AOMSI is more than an association—it's a powerhouse of surgical excellence, collaboration, and innovation. It refines our clinical acumen, hones our surgical skills, and keeps us at the forefront of modern advancements. Beyond surgery, it fosters personal and social growth, creating a strong network where we learn, share, and evolve alongside pioneers in the field. With grants for research, innovation, and new treatment modalities, AOMSI empowers us to push boundaries. It's not just a professional body; it's a family that uplifts, supports, and drives progress, ensuring we grow together and set new benchmarks in maxillofacial surgery.

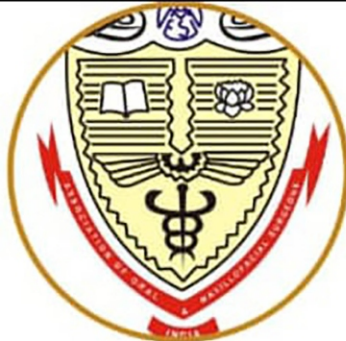

Tickle



Times



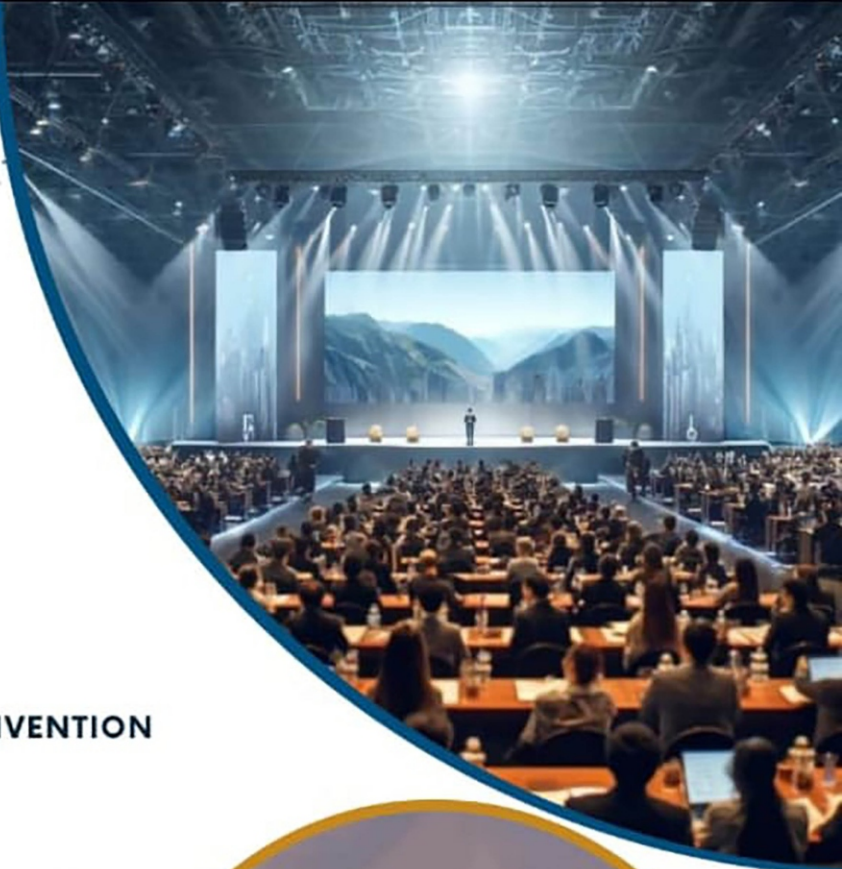

**AOMSI UTTAR
PRADESH STATE
CHAPTER**

MIDCOMS

2025

**27th AOMSI MID TERM & 13TH PG CONVENTION
OF AOMSI**



1

Current tariff valid till 15th Feb

2

Rs. 500 HIKE FROM 16th Feb ONWARDS

3

Delegate AOMSI Member- Rs. 8000/-

Delegate Non-AOMSI Member- Rs. 10000/-

PG Student AOMSI Member- Rs. 6500/-

PG Student Non-AOMSI Member- Rs. 8500/-

Accompanying person- Rs.7500/-



DATE

10th -12th JULY 2025

VENUE

DOUBLE TREE BY HILTON, AGRA

HURRY

**This tariff rate expires on
15 February 2025**



www.midcoms2025.com

SCAN ME TO REGISTER

PLEASE ENCOURAGE YOUR FACULTIES AND PG FOR EARLY REGISTRATION

